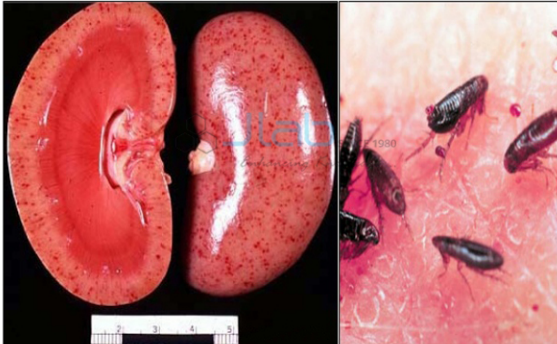

**Malignant Nephrosclerosis**  
**Flea bitten Kidney**

**Product Code . JL-BE-5186**

**Malignant Nephrosclerosis, Flea Bitten Kidney Model**



**Description**

---

Malignant Nephrosclerosis, Flea Bitten Kidney Model

May see narcotizing glomerulitis, wrinkling and collapse of capillary walls and small crescents.

Myointimal hyperplasia and hypertrophy is associated with acute or persistent severe high blood pressure.

Fibroid necrosis of arterioles, hyper plastic arterioles(onion skinning) due to concentric layering of collagen.

Necrotizing arteriolitis:-

Fibrinoid necrosis of afferent arteriole, often superimposed on hyperplastic or hyaline lesions; media has deposits of deeply eosinophilic and fibrillar material containing fibrin and fibrinogen.

Early changes:-

Profound intimal thickening by myxoid connective tissue, reducing lumen.

---




Late changes:-

Scarring and concentric thickening of vessel wall by myointimal cells and deposition of basement membrane type material (onion skinning).

**Biology Equipment Manufacturer India, Biology Equipment Exporters, Physics Lab Equipment Malignant Nephrosclerosis, Flea Bitten Kidney Model, Buy Malignant Nephrosclerosis, Flea Bitten Kidney Model Online India, Malignant Nephrosclerosis, Flea Bitten Kidney Model Suppliers, Didactic, Didactic Malignant Nephrosclerosis, Flea Bitten Kidney Model, Educational Equipment.**

```
{ "@context": "http://schema.org/", "@type": "Product", "name": "Malignant Nephrosclerosis, Flea Bitten Kidney Model", "image": "https://www.jlabexport.com/images/catalog/product/1421652549MalignantNephrosclerosis,FleaBittenKidneyModel.jpg", "description": "Malignant Nephrosclerosis, Flea Bitten Kidney Model May see narcotizing glomerulitis, wrinkling and collapse of capillary walls and small crescents. Myointimal hyperplasia and hypertrophy is associated with acute or persistent severe high blood pressure. Fibroid necrosis of arterioles, hyper plastic arterioles(onion skinning) due to concentric layering of collagen. Necrotizing arteriolitis:- Fibrinoid necrosis of afferent arteriole, often superimposed on hyperplastic or hyaline lesions; media has deposits of deeply eosinophilic and fibrillar material containing fibrin and fibrinogen. Early changes:- Profound intimal thickening by myxoid connective tissue, reducing lumen. Late changes:- Scarring and concentric thickening of vessel wall by myointimal cells and deposition of basement membrane type material (onion skinning). Biology Equipment Manufacturer India, Biology Equipment Exporters, Physics Lab Equipment Malignant Nephrosclerosis, Flea Bitten Kidney Model, Buy Malignant Nephrosclerosis, Flea Bitten Kidney Model Online India, Malignant Nephrosclerosis, Flea Bitten Kidney Model Suppliers, Didactic, Didactic Malignant Nephrosclerosis, Flea Bitten Kidney Model, Educational Equipment.", "brand": "Jlab Export", "sku": "5", "gtin8": "5", "gtin13": "5", "gtin14": "5", "mpn": "5", "aggregateRating": { "@type": "AggregateRating", "ratingValue": "5", "bestRating": "5", "worstRating": "0", "ratingCount": "5" } }
```

---

Jain Laboratory Instruments Pvt. Ltd,  
Hargolal Road, Ambala Cantt, Haryana India  
Direct Contact Details  +91-8569909696  sales@jlabexport.com  
 www.jlabexport.com